

Evaluation of the Acute Toxicity of the Ethanolic Extract of the Rhizome of *Zingiber officinale* Roscoe in Rats

Víctor E. Villarreal-La Torre¹, Juana E. Chávez-Flores², Carmen R. Silva-Correa^{1,*}, Abhel A. Calderón-Peña³, Cinthya L. Aspajo-Villalaz³, Julio Hilario-Vargas⁴, Maria J. Abanto-Vaella⁴, César D. Gamarra-Sánchez¹, Yuri F. Curo-Vallejos¹, Marco L. Salazar-Castillo³, Icela M. Rodríguez-Haro³, Flor Soriano-López³, Renato Cueva-Veneros⁵, José L. Cruzado-Razco¹

Víctor E. Villarreal-La Torre¹, Juana E. Chávez-Flores², Carmen R. Silva-Correa^{1,*}, Abhel A. Calderón-Peña³, Cinthya L. Aspajo-Villalaz³, Julio Hilario-Vargas⁴, Maria J. Abanto-Vaella⁴, César D. Gamarra-Sánchez¹, Yuri F. Curo-Vallejos¹, Marco L. Salazar-Castillo³, Icela M. Rodríguez-Haro³, Flor Soriano-López³, Renato Cueva-Veneros⁵, José L. Cruzado-Razco¹

¹Facultad de Farmacia y Bioquímica, Universidad Nacional de Trujillo, PERÚ.

²Facultad de Farmacia y Bioquímica, Universidad Norbert Wiener, PERÚ.

³Facultad de Ciencias Biológicas, Universidad Nacional de Trujillo, PERÚ.

⁴Facultad de Medicina, Universidad Nacional de Trujillo, PERÚ.

⁵Universidad Nacional de Frontera, PERÚ.

Correspondence

Carmen R. Silva-Correa

Facultad de Farmacia y Bioquímica, Universidad Nacional de Trujillo, PERÚ.

E-mail: csilva@unitru.edu.pe

History

- Submission Date: 12-02-2024;
- Review completed: 16-03-2024;
- Accepted Date: 27-03-2024.

DOI : 10.5530/pj.2024.16.49

Article Available online

<http://www.phcogj.com/v16/i2>

Copyright

© 2024 Phcogj.Com. This is an open-access article distributed under the terms of the Creative Commons Attribution 4.0 International license.

ABSTRACT

Background: Ginger has pharmacological activities such as anticancer, antidiabetic, antioxidant, antimicrobial, anti-neuroinflammatory, and chemotherapy-induced nausea and vomiting. **Objective:** The research aims to evaluate the acute toxicity of the ethanolic extract of the rhizome of *Zingiber officinale* Roscoe in rats. **Materials and Methods:** The extract was administered at doses of 300 and 2000 mg/Kg/day to female and male rats. Changes in body weight were determined during the 14-day treatment period, and on the last day of treatment, blood was drawn, and euthanasia was performed, removing organs for histological analysis. Biochemical parameters were measured. **Results:** The body weight of the research specimens not show statistically significant variation. In the liver, mild lymphocytic portal inflammation and moderate hepatic steatosis occurred at doses of 2000 mg/kg/day. The kidneys exhibited a mild infiltration around the renal tubules and glomeruli at the same dose. The brain showed a slight increase in the count of astrocytes with focal glial reaction at the highest dose. The stomach and heart also showed mild inflammatory processes at the dose of 2000 mg/kg/day. In biochemical parameters, statistically significant differences were observed between the dose of 2000 mg/Kg/day and the control group. **Conclusion:** The ethanolic extract of the rhizome of *Z. officinale* in rats revealed histopathological changes in the liver, kidneys, brain, stomach, and heart, besides changes in biochemical parameters at doses of 2000 mg/Kg/day.

Keywords: *Zingiber officinale*, Acute toxicity test, Histopathology, Biochemical parameters, Rats.

INTRODUCTION

Ginger (*Zingiber officinale*) is an herbaceous, perennial, rhizomatous plant that belongs to the Zingiberaceae family.¹ This plant is endemic to India and cultivated in South and South-East Asia, Africa, Latin America and Australia.² The rhizome of ginger has been processed into powder, syrup, volatile oil, and oleoresin. Clinical trials indicate that ginger can be ingested to alleviate nausea and vomiting induced by surgery, pain, diabetes, obesity, inflammation, male infertility, flatulent intestinal colic, indigestion, insomnia, to treat memory loss, rheumatism, stomach pain, and urinary tract infections.³⁻⁴ Ginger has pharmacological activities such as antidiabetic⁵, antioxidant⁶, anticancer⁷, anti-neuroinflammatory⁸, antibacterial⁹⁻¹¹, antiobesity¹², immunomodulatory and antiallergic.¹³

There are many compounds isolated from ginger. These can be classified into seven categories, which cover volatile oils such as α -zingiberene, which is the main component of the volatile oil of *Z. officinale*¹⁴, terpenoid analogues consisting mainly of monoterpene and sesquiterpene¹⁵, flavonoids¹⁴, gingerol analogues such as gingerol, shogaol, zingerone, paradol, gingerdione and gingerdiol¹⁶, diarylheptanoids that are a class of compounds with 1,7-disubstituted phenyl groups and a heptane structure, thus we have curcumin¹⁴, organic acids that can be differentiated into fatty acids, aromatic

acids, oxalic and tartaric acids¹⁷, steroids, such as daucoesterol and 24-propyl cholesterol. Gingerols are the main functional components and the characteristic aromatic ingredients of the Zingiber genus.¹⁶

Plant species are currently important for their various therapeutic uses and play a significant role in traditional medicine. So, an evaluation of their safety profile must be carried out through toxicological studies. This study was carried out to evaluate the acute toxicity of the ethanolic extract of the rhizomes of *Zingiber officinale* on the biochemical and histopathological parameters of Albino Holtzman rats.

MATERIALS AND METHODS

Collection of the plant species

The rhizomes of *Zingiber officinale* Roscoe were collected in the town of Alto Toterani annex, Perenne district, Chanchamayo Province, Junín Department, Peru. The selected plant species were taken to the Natural History Museum of the Universidad Nacional Mayor de San Marcos for taxonomic identification (Proof N°293-UNMSM-2018).

Preparation of the ethanolic extract

500 g of fresh rhizomes of *Zingiber officinale* Roscoe were weighed and, with 1 L of 95% ethanol, were

Cite this article: Villarreal-La Torre VE, Chávez-Flores JE, Silva-Correa CR, Calderón-Peña AA, Aspajo-Villalaz CL, Hilario-Vargas J, et al. Evaluation of the Acute Toxicity of the Ethanolic Extract of the Rhizome of *Zingiber officinale* Roscoe in Rats. Pharmacogn J. 2024;16(2): 323-331.

macerated for 7 days in a hermetically sealed amber bottle, and the mixture was shaken daily for 7 days. At the end of this period, it was filtered and concentrated in a rotary evaporator, then taken to an oven at a temperature of 40°C to dry and obtain the dry extract.¹⁸

Experimental animals and housing

Both female and male Holtzman albino rats (250 - 300 g), aged 16 to 20 weeks, were used in this study. Rats were maintained in individual cages and were exposed to a 12-hour light/12-hour dark cycle, with a temperature of 22 ± 3 °C. They were provided with a standard laboratory diet and water administered *ad libitum*. The rats underwent an acclimatization period for 2 weeks before carrying out the study.¹⁹

Acute toxicity test

The test was carried out according to the method described in OECD regulation No. 423. Experimental groups were formed, each with 10 rats (5 males and 5 females). The Control Group was administered 2 mL of physiological saline solution (SSF 0.9%). Problem Group I was administered the ethanolic extract of *Zingiber officinale* Roscoe rhizomes in a single dose of 300 mg/Kg/day. Problem Group II was administered the ethanolic extract of *Zingiber officinale* Roscoe rhizomes in a single dose of 2000 mg/Kg/day. The body weight of the rats was measured three times, once before administering the extract and on days 7 and 14 of observation.¹⁹

The animal study protocol was approved by the Ethics Committee of the Faculty of Medicine the Universidad Nacional de Trujillo (Approval Certificate No.: 372 - 2022/ UNT-FM-C.E.).

Blood biochemistry evaluation

On day fourteen, after the treatments were administered, blood was obtained from the specimens through cardiac puncture. Plasma was separated by centrifugation at 2000 rpm for 15 minutes in a refrigerated centrifuge (4°C) and stored at -80°C. The biochemical parameters that were measured are urea, creatinine, aspartate transaminase (AST), alanine transaminase (ALT), alkaline phosphatase (ALP), cholesterol, and triglycerides.¹⁹

Histopathological analysis

The animals were euthanized using sodium pentobarbital 60 mg/kg intraperitoneally. The brain, heart, lung, kidney, liver, stomach, uterus, ovary, prostate, and testicles were extracted, preserved in 10% formalin, and then taken to the corresponding histological study.¹⁹

Statistical analysis

Statistical analysis was performed using the R-4.1.1 program (free software) for Windows®, and the data were subjected to analysis of variance (ANOVA) followed by posthoc (Tukey's test). The values were considered statistically significant when $p < 0.05$.

RESULTS

Changes in body weight

The determination of the body weight of the rats was carried out after the administration of the *Zingiber officinale* extract, as well as on days 7 and 14, observing variation in the weights on day 14 post-treatment, although this variation is not statistically significant.

Biochemical parameters

In Figure 2, a significant difference is observed in the AST values between the Control, *Zingiber officinale* 300, and *Zingiber officinale* 2000 groups in both males and females, with the AST concentration increasing as the dose of *Zingiber officinale* extract increases ($p < 0.05$). In the ALT and ALP values, only the *Zingiber officinale* 2000 group is statistically different, with the Control group and *Zingiber officinale* 300 being statistically similar to each other ($p < 0.05$). Cholesterol, triglycerides, urea, and creatinine were measured, observing significant differences in all these parameters in the *Zingiber officinale* 2000 group ($p < 0.05$) in both males and females (Figure 3).

Histopathological analysis

The liver tissue of the group that received the *Z. officinale* extract shows mild lymphocytic portal inflammation, hepatocytes with condensed nuclei, and the presence of eosinophilia, as well as moderate hepatic steatosis; this effect is observed at the dose of 2000 mg/kg, in comparison to the control group. The kidneys at the same dose show a slight infiltrate with the presence of lymphocytes and some polymorphonuclear cells around renal tubules and glomeruli in the region of the renal cortex, as well as in the brain tissue in which a slight increase in the number of astrocytes with reaction mild focal glial is observed (Figure 4). The lung tissue does not show histological alterations in bronchi or bronchioles in both males and females. The fundic gastric mucosa shows normal glandular cells: mucinous, parietal, and main cells distributed normally in its three regions, with a slight inflammatory infiltrate between them made up of some lymphocytes and polymorphonuclear cells at the dose of 2000 mg/kg, as well as in the cardiac tissue, which shows in

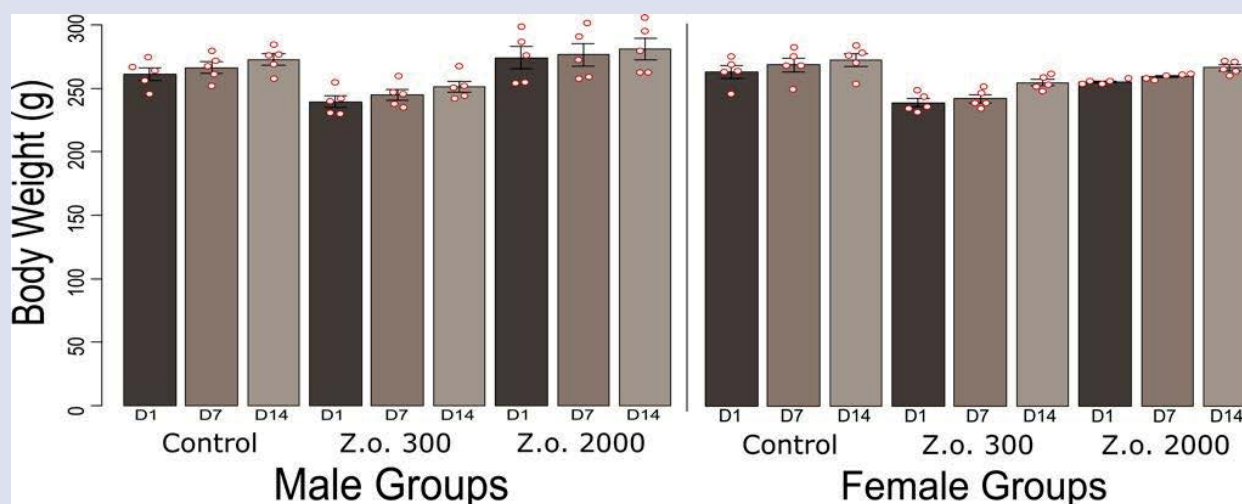


Figure 1: Body weight of rat in the treated and control groups during the 14-day acute toxicity assessment

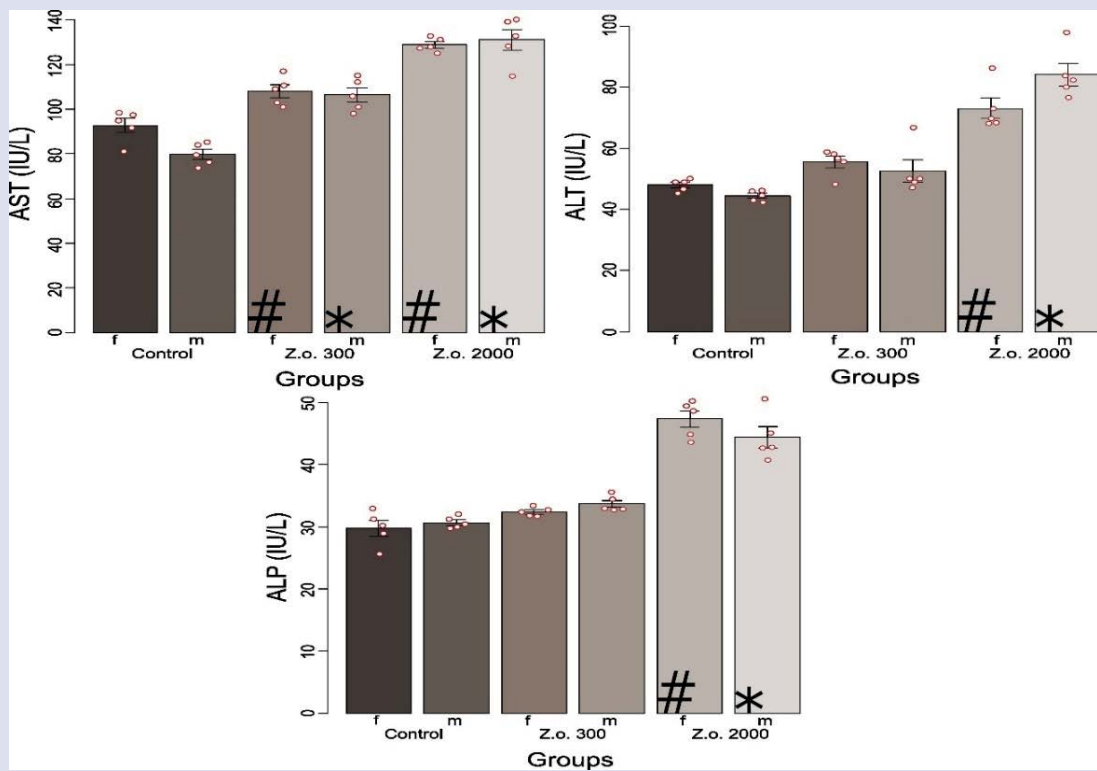


Figure 2: Biochemical parameters (AST, ALT and ALP) of rat serum after acute oral administration of extracts of *Zingiber officinale* Roscoe. #: A statistically significant difference was observed with Control female group; *: A statistically significant difference was observed with Control male group, according to the ANOVA statistical analysis ($p < 0.05$) and Tukey's post hoc test

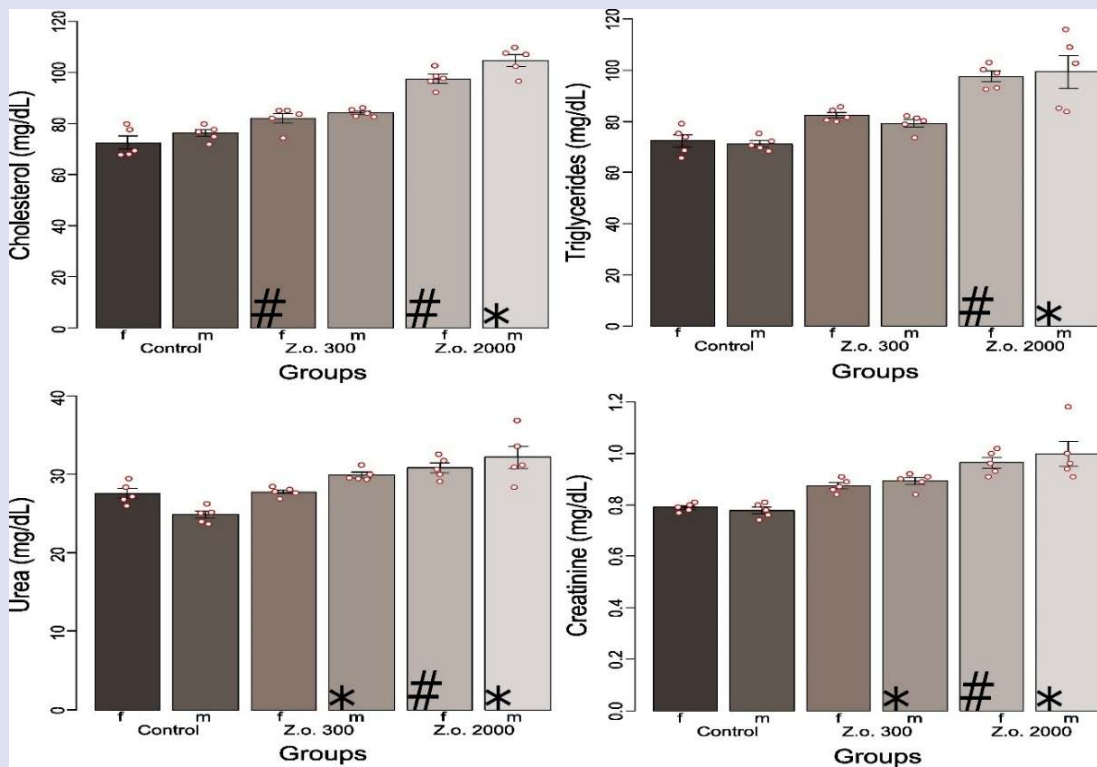


Figure 3: Biochemical parameters (cholesterol, triglycerides, urea, creatinine) of rat serum after acute oral administration of extracts of *Zingiber officinale* Roscoe. #: A statistically significant difference was observed with Control female group; *: A statistically significant difference was observed with Control male group, according to the ANOVA statistical analysis ($p < 0.05$) and Tukey's post hoc test

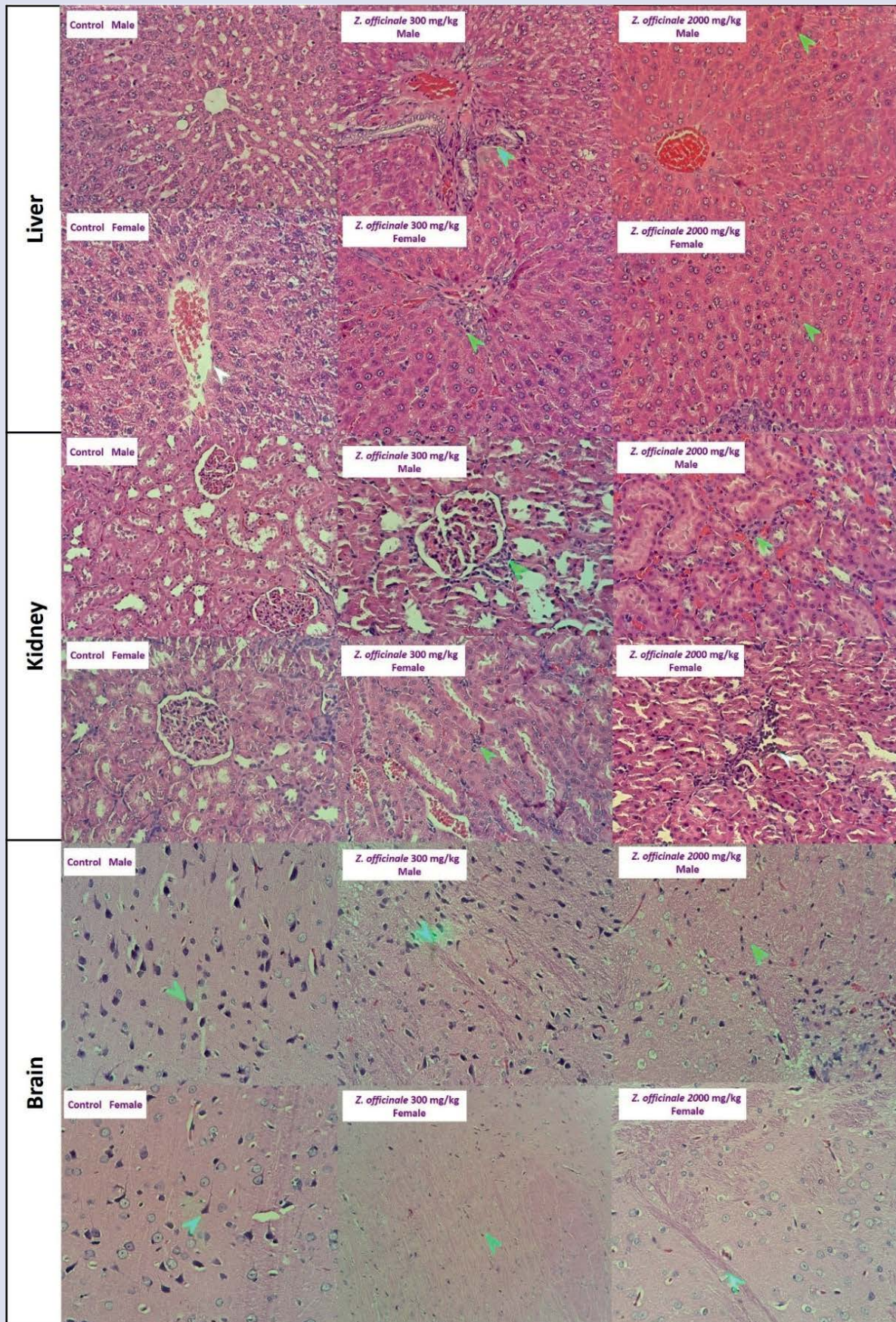


Figure 4: Photomicrographs of histological sections from liver, kidney, and brain of Holtzman rats treated with aqueous extract of *Zingiber officinale* Roscoe

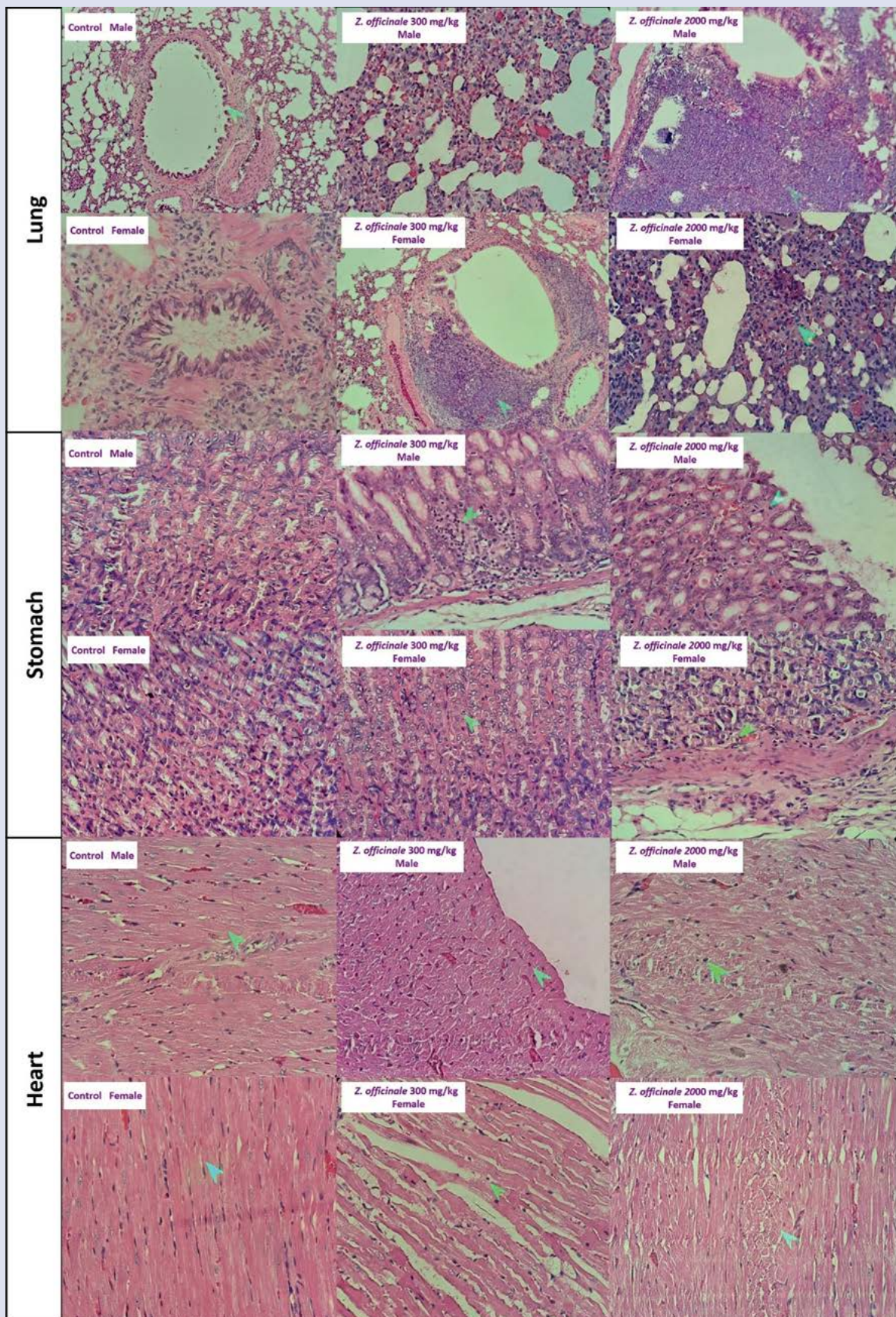


Figure 5: Photomicrographs of histological sections from lung, stomach, and heart of Holtzman rats treated with aqueous extract of *Zingiber officinale* Roscoe

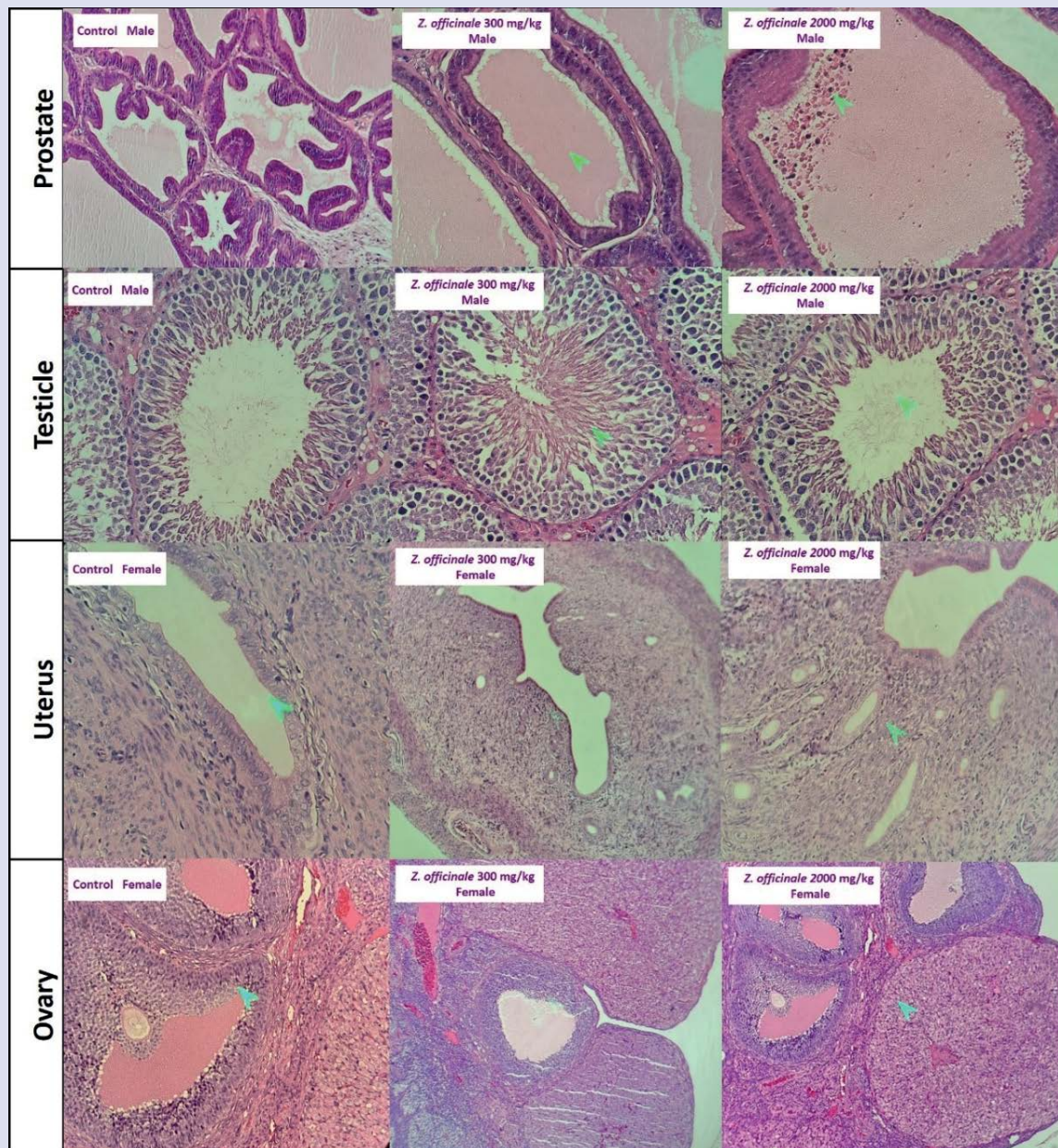


Figure 6: Photomicrographs of histological sections from prostate, testicle, uterus, and ovary of Holtzman rats treated with aqueous extract of *Zingiber officinale* Roscoe

both males and females some polymorphonuclear cells between the cardiomyocytes between the cardiac fibers. All these effects are dose-dependent (Figure 5).

In male rats, prostate glands vary slightly in shape and size, are observed in moderate quantity, and are covered by simple pseudostratified epithelium without atypia. They have oval nuclei, separated by a moderate amount of stroma, which does not show alterations at the dose of 300 mg/day/kg. At the dose of 2000 mg/kg, the prostate shows mild inflammation containing some polymorphonuclear cells and lymphocytes in its lumen. The testes in the experimental groups do not show damage, with the presence of testicular parenchyma with seminiferous tubules of normal conformation, containing spermatogenic cells in different phases of differentiation, the presence of Sertoli cells, Spermatogonia, secondary spermatocytes, spermatids and mature spermatozoa in the tubular lumen, the stroma shows a

moderate amount of Leydig cells, with preserved vascularization and no inflammatory infiltrate or neoplastic changes are observed. While in female rats at doses of 300 mg/kg and 2000 mg/kg, the uterine wall is observed with a normal conformation of its three layers: endometrium, myometrium, and perimetrium, the smooth muscle fibers of the myometrium have a normal arrangement, tapered shapes with oval nuclei without atypia, surrounded by a stroma with adequate vascularization. The ovaries at both doses show ovarian follicles in different phases of differentiation, with primary and secondary follicles and corpora lutea with normal characteristics (Figure 6).

DISCUSSION

The rhizome of *Zingiber officinale* is very useful in the culinary field; however, the doses usually used are low compared to therapeutic uses, which is why a toxicity study is of great importance despite being a highly consumed product over time. The experimental animals'

weights are observed to 14 days of treatment. Although a slight increase in this is observed at 7 and 14 days of treatment, it is not statistically significant. If the treatment had been for a longer time, higher variation could have been observed and determined if the consumption of the ethanolic extract of *Zingiber officinale* produces changes in the weight of the experimental animals, as mentioned by Attari E. *et al* (2016), a study in which *Zingiber officinale* was administered to obese women for 12 weeks and a decrease in weight was observed (Figure 1).²⁰

The measurement of the liver markers AST, ALT, and ALP was carried out. These markers are widely used in the detection of liver diseases and reflect liver damage.²¹⁻²² The analysis of liver function is important for evaluating the toxicity of plant extracts.²³ In both the female and male groups, a statistically significant elevation of the three parameters is observed in the group that received the *Zingiber officinale* 2000 extract. This may be due to the high concentration of the extract (Figure 2). AST is a marker in the evaluation of the integrity of the plasma membrane, and its isolated elevation in serum is an indicator of damage to the plasma membrane, which leads to liver or heart damage.²⁴⁻²⁵

It is shown that urea and creatinine levels increase in the *Zingiber officinale* 2000 group (Figure 3) compared to the control group ($p < 0.05$). These parameters are of greater importance to be measured since they are considered sensitive biomarkers of kidney damage.²¹ Plasma urea generally increases in kidney diseases, and its clearance decreases when the kidney fails, while creatinine is produced endogenously, released into body fluids at a constant rate, and its plasma concentration is maintained by glomerular filtration. Serum urea values of normal adult rats are measured between 15 and 45 mg/dl, and creatinine in adult rats is approximately 0.2 to 0.8 mg/dl²⁶, so in this study, the mean values of urea would be within the normal range, but creatinine levels would show a slight significant increase.

Histological changes in the liver show a dose-dependent toxic effect, with the presence of mild liver damage in the liver parenchyma and mild lymphocytic portal inflammation, showing mild steatosis at the dose of 2000 mg/kg (Figure 4). This is related to the parameters of AST, ALT, and ALP that were also observed to increase (Figure 2). A previous study has shown that *Z. officinale* extract at doses of 300 and 600 mg/kg prevents liver injury in a model of liver fibrosis induced by carbon tetrachloride in male Wistar rats, observing a decrease in inflammation, modulating the TGF- β 1/Smad3 and NF- κ B/I κ B signaling pathways.²⁷ Furthermore, the *Z. officinale* extract has higher antioxidant capacity thanks to the bioactive compounds that this plant has²⁸, so the damage observed in this study at the dose of 2000 mg/kg may be caused by a prooxidant effect of the antioxidants that depend on the dose of these.²⁹

The renal tissue shows a slight inflammatory infiltrate with the presence of lymphocytes and some polymorphonuclear cells around renal tubules and glomeruli at the dose of 2000 mg/kg, compared to the control group, which shows renal parenchyma without histological alterations (Figure 4). This effect is related to the levels of urea and creatinine that were also observed to be increased in the group that received doses of 2000 mg/kg (Figure 3). Studies show nephroprotective effects in rats treated with *Z. officinale* extract with reversal of histomorphological changes in kidney tissues in animals exposed to fluoride.³⁰ The nephroprotective and antioxidant potential of ginger against kidney lesions in osteoporotic rats was also confirmed. Analysis by HPLC revealed that *Z. officinale* contained appreciable amounts of phenols and flavonoids and exhibited high purifying activity³¹. Regarding high doses of *Z. officinale* extract (2000 mg/Kg), it has been shown that these large amounts of antioxidant substances can cause damage due to antioxidative stress.²⁹

The brain tissue of the experimental groups shows normal histological characteristics, with a slight increase in the number of astrocytes and

glial response to the dose of 2000 mg/kg, while the rest of the brain tissue shows conservation of its normal architectural conformation. The Zingiberaceae family has several bioactive compounds with significant systemic activities in the brain; these compounds can affect the expression of neurotrophic agents.³² *Z. officinale* extract protects lipid peroxidation in brain homogenate; this protection mechanism is correlated with the property of this extract to eliminate free radicals.³³ Likewise, *Z. officinale* was effective in ameliorating and protecting against the neurotoxic effects of reserpine in the hippocampus.³⁴ One of the bioactive compounds is 6-shogaol, which showed significant neuroprotective effects in an *in vivo* model of transient global ischemia through inhibition of microglia by repressing the production of prostaglandin E2, interleukin-1 β , and tumor necrosis factor- α , and by downregulating cyclooxygenase-2, p38 mitogen-activated protein kinase (MAPK), and nuclear factor kappa B (NF- κ B) expression.³⁵

On the other hand, in brain samples with doses of 2000 mg/Kg, the excess of bioactive antioxidant compounds may be the cause of the glial reaction and inflammation. Reductive stress (oxidative stress) is harmful to the structure and neuronal function, which can affect neurogenesis through protein misfolding and endoplasmic reticulum dysfunction, promoting protein aggregation and proteotoxicity.³⁶ The use of excessive antioxidants causes reductive stress, which disturbs the functionality of the blood-brain barrier and angiogenic properties and has adverse implications for the regulation of the brain's homeostatic environment. Thus, irresponsible treatment with antioxidants tends to mitigate reactive oxygen species (ROS)-induced stimulation of normal cellular mechanisms, including cell proliferation, membrane permeability and transport, and mitochondrial function.³⁷

In the histological analysis of lung tissue, no histopathological changes were observed in the structures of bronchi and bronchioles (Figure 5). No changes were observed in the gastric and cardiac tissues at the dose of 300 mg/Kg, likely due to the antioxidant properties of *Z. officinale*, which prevent oxidative stress and inflammation. This antioxidant capacity is attributed to compounds present in this root, such as 10-gingerol and 6-shogaol.³⁸ However, at the dose of 2000 mg/Kg (Figure 5), a slight inflammatory process is evident in both gastric and cardiac tissues. This effect is most likely caused by an excess of the same substances that, at a lower concentration (300 mg/Kg), provide the antioxidant characteristic of *Z. officinale*. Some food components, such as polyphenols, flavonoids, and carotenoids, among other compounds, have cytoprotective and antioxidant activity.³⁹ However, these can also exhibit prooxidant activities when consumed in high doses or when metal ions are present. The concentration determines their prooxidant and/or antioxidant activity.⁴⁰⁻⁴¹ This prooxidant activity of the substances contained in the extract of *Z. officinale* at high doses (2000 mg/Kg) could be involved in the inflammation observed in gastric and cardiac tissues. Thus, high levels of flavonoids can cause cytotoxicity, DNA damage, apoptosis, and the presence of ROS due to autooxidation.⁴² Likewise, phenolic antioxidants show prooxidant activities in the presence of transition metal ions such as iron and copper at high concentrations, forming chelators and reducing antioxidant capacity.⁴³

The *Z. Officinale* extract does not generate any change in the testicular parenchyma, which is composed of normally conformed seminiferous tubules. These tubules contain spermatogenic cells in different phases of differentiation, with the presence of Sertoli cells, spermatogonia, secondary spermatocytes, spermatids, and mature spermatozoa in the tubular lumen. The testicle shows its thin albugineal layer with normal characteristics. No inflammatory infiltrate or neoplastic changes were observed. In contrast, the prostate shows acute inflammation and suppurative cryptitis, with some prostate glands containing polymorphonuclear cells and lymphocytes in their lumen, but only at the dose of 2000 mg/kg of the *Z. Officinale* extract. This is in comparison

to the control group, which shows a simple pseudostratified epithelium without atypia, with oval nuclei, separated by a moderate amount of stroma (Figure 6).

In female rats, the ovary displays ovarian follicles in different phases of differentiation, including primary and secondary follicles, as well as corpora lutea with normal characteristics. The endometrium and endometrial glands exhibit a ciliated pseudostratified epithelial lining without atypia, along with smooth muscle fibers. The myometrium has a normal arrangement, with tapered shapes and oval nuclei without atypia, surrounded by a stroma with adequate vascularization. It is only at the dose of 2000 mg/kg that the endometrial stroma shows a slight inflammatory infiltrate (Figure 6).

CONCLUSIONS

The acute toxicity evaluation of the ethanollic extract of the rhizome of *Zingiber officinale* Roscoe in rats revealed histopathological changes, mainly at the dose of 2000 mg/kg. The liver showed mild lymphocytic portal inflammation, condensed hepatocyte nuclei, eosinophilia, and moderate hepatic steatosis. The kidneys exhibited a mild infiltration of lymphocytes and some polymorphonuclear cells around the renal tubules and glomeruli at the same dose. The brain showed a slight increase in the number of astrocytes with focal glial reaction, and the stomach and heart also showed mild inflammatory processes. Biochemical parameters such as cholesterol, triglycerides, AST, ALT, ALP, urea, and creatinine in rat serum showed statistically significant differences between the dose of 2000 mg/Kg/day and the control group.

CONFLICTS OF INTEREST

The authors declare no conflicts of interest.

REFERENCES

- Mao QQ, Xu XY, Cao SY, Gan RY, Corke H, Beta T, et al. Bioactive Compounds and Bioactivities of Ginger (*Zingiber officinale* Roscoe). *Foods*. 2019;8(6):1-21.
- Khodaie L, Sadeghpour O. Ginger from ancient times to the new outlook. *Jundishapur J Nat Pharm Prod*. 2015;10(1):e18402
- Ali A, Gilani AH. Medicinal value of Ginger with focus on its use in nausea and vomiting of pregnancy. *Int J Food Prop*. 2007;10(2):269-78.
- Unuofin JO, Masuku NP, Paimo OK, Lebelo SL. Ginger from Farmyard to Town: Nutritional and Pharmacological Applications. *Front Pharmacol*. 2021;12(1):1-28.
- Zhu J, Chen H, Song, Z, Wang X, Sun Z. Effects of Ginger (*Zingiber officinale* Roscoe) on Type 2 Diabetes Mellitus and Components of the Metabolic Syndrome: A Systematic Review and Meta-Analysis of Randomized Controlled Trials. *Evid Based Complement Alternat Med*. 2018;2018(1):1-11.
- Mustafa I, Chin NL. Antioxidant Properties of Dried Ginger (*Zingiber officinale* Roscoe) var. Bentong. *Foods*. 2023;12(1):1-18.
- Crichton M, Marshall S, Marx W, McCarthy AL, Isenring, E. Efficacy of Ginger (*Zingiber officinale*) in Ameliorating Chemotherapy-Induced Nausea and Vomiting and Chemotherapy-Related Outcomes: A Systematic Review Update and Meta-Analysis. *J Acad Nutr Diet*. 2019;119(12):2055-68.
- Ho SC, Chang KS, Lin CC. Anti-neuroinflammatory capacity of fresh ginger is attributed mainly to 10-gingerol. *Food Chem*. 2013;141(3):3183-91.
- Aji N, Kumala S, Mumpuni E, Rahmat D. Antibacterial Activity and Active Fraction of *Zingiber officinale* Roscoe, *Zingiber montanum* (J.Koenig) Link ex A., and *Zingiber zerumbet* (L.) Roscoe ex Sm. Against *Propionibacterium acnes*. *Pharmacogn J*. 2022;14(1):103-11.
- Wibowo DP, Mariani R, Hasanah SU, Aulifa DL. Chemical Constituents, Antibacterial Activity and Mode of Action of Elephant Ginger (*Zingiber officinale* var. *officinale*) and Emprit Ginger Rhizome (*Zingiber officinale* var. *amarum*) Essential Oils. *Pharmacogn J*. 2020;12(2):404-9.
- Sharma PK, Singh V, Ali M. Chemical Composition and Antimicrobial Activity of Fresh Rhizome Essential Oil of *Zingiber Officinale* Roscoe. *Pharmacogn J*. 2016;8(3):185-190.
- Nazish I, Ansari SH, Arora P, Ahmad A. Antiobesity activity of *Zingiber officinale*. *Pharmacogn J*. 2016;8(5):440-6.
- Lalruatfela B, Lalthanpu P, Lalrinmawia C, Lalhchandama K. Immunomodulatory and Antiallergic Potentials of the Bioactive Compounds of Ginger. *Pharmacogn J*. 2023;15(6):1166-76.
- Deng M, Yun X, Ren S, Qing Z, Luo F. Plants of the Genus *Zingiber*: A Review of Their Ethnomedicine, Phytochemistry and Pharmacology. *Molecules*. 2022;27(9):1-25.
- Abe M, Ozawa Y, Uda Y, Yamada F, Morimitsu Y, Nakamura Y, et al. Antimicrobial activities of diterpene dialdehydes, constituents from *Myoga* (*Zingiber mioga* Roscoe), and their quantitative analysis. *Biosci Biotechnol Biochem*. 2004;68(7):1601-04.
- Liu Y, Liu J, Zhang Y. Research Progress on Chemical Constituents of *Zingiber officinale* Roscoe. *Biomed Res Int*. 2019;19(1):1-21.
- Yeh H, Chuang C, Chen H, Wan CJ, Chen TL, Lin LY. Bioactive components analysis of two various gingers (*Zingiber officinale* Roscoe) and antioxidant effect of ginger extracts. *LWT - Food Science and Technology*. 2014;55(1):329-34.
- Chang CJ, Tzeng TF, Liou SS, Chang YS, Liu IM. Acute and 28-day subchronic oral toxicity of an ethanol extract of *Zingiber zerumbet* (L.) Smith in rodents. *Evid Based Complement Alternat Med*. 2012;12(1):1-12.
- Silva-Correa CR, Villarreal-La Torre VE, González-Siccha AD, Cruzado-Razco JL, González-Blas MV, Sagástegui-Guariz WA, et al. Acute toxicity of aqueous extract of *Ambrosia arborescens* Mill. on biochemical and histopathological parameters in rats. *Toxicol Res*. 2021;38(2):225-33.
- Attari E, Ostadrahimi A, Asghari JM, Mehrizadeh S, Mahluji S. Changes of serum adipocytokines and body weight following *Zingiber officinale* supplementation in obese women: a RCT. *Eur J Nutr*. 2016;55(6):2129-36.
- El Kabbaoui M, Chda A, El-Akhal J, Azdad O, Mejrhit N, Aarab L, et al. Acute and sub-chronic toxicity studies of the aqueous extract from leaves of *Cistus ladaniferus* L. in mice and rats. *J Ethnopharmacol*. 2017;209(1):147-56.
- Hassanzadeh-Taheri M, Hosseini M, Salimi M, Moodi H, Dorranipour D. Acute and sub-acute oral toxicity evaluation of *Astragalus hamosus* seedpod ethanollic extract in wistar rats. *Pharm Sci*. 2018;24(1):23-30.
- Al-Afifi NA, Alabsi AM, Bakri MM, Ramanathan A. Acute and sub-acute oral toxicity of *Dracaena cinnabari* resin methanol extract in rats. *BMC Complement Alternat Med*. 2018;18(1):1-14.
- Ndrepepa G. Aspartate aminotransferase and cardiovascular disease - A narrative review. *J Lab Precis Med*. 2021;6(6):1-17.
- Balogun FO, Ashafa AO. Acute and subchronic oral toxicity evaluation of aqueous root extract of *Dicoma anomala* Sond. in Wistar Rats. *Evid Based Complement Alternat Med*. 2016;16(1):1-12.
- Loha M, Mulu A, Abay SM, Ergete W, Geleta B. Acute and Subacute Toxicity of Methanol Extract of *Syzygium guineense* Leaves on the Histology of the Liver and Kidney and Biochemical Compositions of Blood in Rats. *Evid Based Complement Alternat Med*. 2019;19(1):1-16.
- Hasan IH, El-Desouky MA, Hozayen WG, Abd GM. Protective Effect of *Zingiber officinale* against CCl₄-Induced Liver Fibrosis Is

- Mediated through Downregulating the TGF- β 1/Smad3 and NF- κ B/I κ B Pathways. *Pharmacology*. 2016;97(1-2):1-9.
28. Bekkouch O, Dalli M, Harnafi M, Touiss I, Mokhtari I, Assri S, et al. Ginger (*Zingiber officinale* Roscoe), Lemon (*Citrus limon* L.) Juices as Preventive Agents from Chronic Liver Damage Induced by CCl₄: A Biochemical and Histological Study. *Antioxidants*. 2022;11(2):1-15.
 29. Villanueva C, Kross RD. Antioxidant-induced stress. *Int J Mol Sci*. 2012;13(2):2091-109.
 30. Sharma P, Verma PK, Sood S, Yousef R, Kumar A, Raina R, et al. Protective Effect of Quercetin and Ginger (*Zingiber officinale*) Extract against Dimethoate Potentiated Fluoride-Induced Nephrotoxicity in Rats. *Foods*. 2023;12(9):1-17.
 31. Zammel N, Jedli O, Rebai T, Hamadou WS, Elkahoui S, Jamal A, et al. Kidney injury and oxidative damage alleviation by *Zingiber officinale*: pharmacokinetics and protective approach in a combined murine model of osteoporosis. *3 Biotech*. 2022;12(5):112-20.
 32. Razak AM, Tan JK, Mohd SM, Makpol S. Modulating Effects of Zingiberaceae Phenolic Compounds on Neurotrophic Factors and Their Potential as Neuroprotectants in Brain Disorders and Age-Associated Neurodegenerative Disorders: A Review. *Nutrients*. 2023;15(11):1-35
 33. Ajith TA. Ameliorating reactive oxygen species-induced in vitro lipid peroxidation in brain, liver, mitochondria and dna damage. *Indian J Clin Biochem*. 2010;25(1): 67-73.
 34. Olanrewaju JA, Owolabi JO, Awodein IP, Enya JI, Adelodun ST, Olatunji SY, et al. *Zingiber officinale* ethanolic extract attenuated reserpine-induced depression-like condition and associated hippocampal aberrations in experimental wistar rats. *J Exp Pharmacol*. 2020;12(1):439-46.
 35. Ha SK, Moon E, Ju MS, Kim DH, Ryu JH, Oh MS, et al. 6-Shogaol, a ginger product, modulates neuroinflammation: A new approach to neuroprotection. *Neuropharmacology*. 2012;63(2):211-23.
 36. Narasimhan KK, Devarajan A, Karan G, Sundaram S, Wang Q, Van Groen T, et al. Reductive stress promotes protein aggregation and impairs neurogenesis. *Redox Biol*. 2020;37(1):1-12.
 37. Fisher D, Mentor S. Antioxidant-induced reductive stress has untoward consequences on the brain microvasculature. *Neural Regen Res*. 2017;12(5):743-4.
 38. Mohd S, Makpol S. Ginger (*Zingiber officinale* Roscoe) in the Prevention of Ageing and Degenerative Diseases: Review of Current Evidence. *Evid Based Complement Alternat Med*. 2019;19(1):1-14.
 39. Xu DP, Li Y, Meng X, Zhou T, Zhou Y, Zheng J, et al. Natural Antioxidants in Foods and Medicinal Plants: Extraction, Assessment and Resources. *Int J Mol Sci*. 2017;18(1):1-32.
 40. Wätjen W, Michels G, Steffan B, Niering P, Chovolou Y, Kampkötter A, et al. Low concentrations of flavonoids are protective in rat H4IIE cells whereas high concentrations cause DNA damage and apoptosis. *J Nutr*. 2005;135(3):525-31.
 41. Pérez-Torres I, Guarnier-Lans V, Rubio-Ruiz ME. Reductive Stress in Inflammation-Associated Diseases and the Pro-Oxidant Effect of Antioxidant Agents. *Int J Mol Sci*. 2017;18(10):1-26.
 42. Hodnick WF, Kung FS, Roettger WJ, Bohmont CW, Pardini RS. Inhibition of mitochondrial respiration and production of toxic oxygen radicals by flavonoids. A structure-activity study. *Biochem Pharmacol*. 1986;35(14):2345-57.
 43. Decker EA. Phenolics: prooxidants or antioxidants? *Nutr Rev*. 1997;55(11):396-8.

Cite this article: Villarreal-La Torre VE, Chávez-Flores JE, Silva-Correa CR, Calderón-Peña AA, Aspajo-Villalaz CL, Hilario-Vargas J, et al. Evaluation of the Acute Toxicity of the Ethanolic Extract of the Rhizome of *Zingiber officinale* Roscoe in Rats. *Pharmacogn J*. 2024;16(2): 323-331.