

Hepatoprotective Activity of *Michelia nilagirica* against Paracetamol Induced Hepatic Injury in Rats

Shaik Aminabee¹, Atmakuri Lakshmana Rao^{*1} and Maram Chinna Eswaraiah²

¹Department of Pharmacology, V. V. Institute of Pharmaceutical Sciences, Gudlavalleru, Andhra Pradesh, INDIA

²Department of Pharmacognosy, Anurag College of Pharmacy, Kodad, Telangana, INDIA.

ABSTRACT

Background: *Michelia nilagirica* belonging to the family Magnoliaceae is commonly used by many traditional healers in most of the herbal preparations for diabetes and kidney diseases. **Objective:** Different fractions isolated from ethanolic extract of whole plant of *Michelia nilagirica* is investigated for hepatoprotective activity in wistar albino rats against paracetamol induced hepatic injury. **Materials & Methods:** Rats were divided into eight groups. Each group contains six animals. Hepatic injury was achieved by injecting paracetamol at a dose of 2 mg/kg p.o. **Results:** The hepatoprotective action is seen with fraction A by reduction in serum marker enzymes like Aspartate transaminase (AST), Alanine transaminase (ALT). It also reduced the elevated levels of Alkaline phosphatase (ALP) & Serum bilirubin. **Conclusion:** Histopathological studies further confined the hepatoprotective activity of fraction A against paracetamol treated group. The results obtained were compared with silymarin (100 mg/kg, orally), a standard drug.

Key words: Albino rats, Hepatoprotective, *Michelia nilagirica*, Paracetamol, Screening.

INTRODUCTION

The liver is a important organ of vertebrates and some other animals and some other animals. It has a wide range of functions like ability to detoxicate toxic substances,¹ synthesis of proteins, production of biochemicals necessary for digestion. Hepatocytes (Liver cells) regulates a variety of biochemical reactions like synthesis and break down of small and complex molecules and many other vital functions. Liver diseases are mainly due to infections, life style (smoking, alcoholism), toxic substances (chemicals & drugs). Hepatotoxic agents damage liver cells by lipid peroxidation and other oxidative damages. In addition, many biochemical markers in the serum like aspartate transaminase² (AST), alanine transaminase (ALT), alkaline phosphatase³ (ALP) and bilirubin⁴ were also increased. In absence of a reliable liver protective drug in the modern system of medicine, a number of novel medicinal

preparations in Ayurveda, Homeopathy, Unani, the Indian system of medicine are recommended for the treatment of liver disorders. So medicinal plants are considered to be effective and safe natural remedy treatments for hepatotoxicity.⁵

Michelia nilagirica, belonging to the genus magnolia (magnoliaceae) is a native to tropical and subtropical South and Southeast Asia, including southern china. It is widely used in both Ayurveda and Homeopathic medicine. Flower buds of *Michelia champaca* Linn. is commonly used by many traditional healers in most of the herbal preparations for diabetes⁶ and kidney diseases.⁷ Traditionally, it is being used in fever, colic, leprosy, post partum protection⁸ and in eye disorders.⁹ It has been reported to possess antipyretic, antiulcer, anti-inflammatory,¹⁰ insecticidal,¹¹ antioxidant, antimicrobial⁸ and leishmanicidal¹² activities. The active constituents reported in this plant are alkaloids, tannins, saponins, sterols, flavonoids and triterpenoids.⁸ In Ayurveda, traditional usages of plants are most commonly in their aqueous extracts form only. Concurrently, some of the papers searched focus for testing these plants in their ethanolic or aqueous extracts and some have also reported activity in petroleum ether, benzene and chloroform

*Corresponding author:

Prof. Atmakuri Lakshmana Rao

Principal, Department of Pharmacology,
V. V. Institute of Pharmaceutical Sciences,
Gudlavalleru-521356, Krishna District, A.P., INDIA.
E-mail: dralrao@gmail.com

DOI: 10.5530/pj.2015.4.4

extracts.¹³⁻¹⁵ Keeping these facts in view, the present study was undertaken to create a scientific base for the use of the extract of *Michelia nilagirica* as a hepatoprotective agent.

Paracetamol is a commonly used analgesic & antipyretic agent. The main adverse effects of paracetamol overdose are hepatotoxicity & nephrotoxicity which could be fatal. Its metabolite N-acetyl-p-benzoquinoneimine (NAPQI) which is normally detoxified by glutathione is responsible for hepatotoxicity. Excess of NAPQI is formed in paracetamol overdose which binds to proteins and other macromolecules resulting in hepatic necrosis. The standard therapy for paracetamol overdose is N-acetylcysteine. It restores hepatic glutathione which detoxifies NAQPI.¹⁶ Some cases do not respond,¹⁷ though N-acetylcysteine is used for the treatment of paracetamol toxicity. In spite of tremendous advances in modern medicine, there are hardly any reliable drugs that protect the liver from damage and/or help in regeneration of hepatocytes. To treat a wide variety of clinical diseases including liver disease many active plant extracts are frequently utilized. Therefore, searching for effective and safe drugs for liver disorders are continues to be an area of interest.¹⁸

MATERIALS AND METHODS

Collection of plant material

The whole plant of *Michelia nilagirica* was collected from the deciduous forest of Tirumala Hills in Andhra Pradesh State, India. Samples were authenticated by Dr. K. Madhava Chetty, Department of Botany, Sri Venkateswara University, Tirupati, India. The whole plant of *Michelia nilagirica* were sorted, cleaned and air-dried at room temperature for one week. By using the laboratory hammer mill these were ground to powder. Powdered samples were collected and stored in air- and water-proof containers protected from direct sunlight and heat until required for extraction.

Preparation of extracts

The powdered materials of *Michelia nilagirica* (whole plant) were extracted successively each for 18 hrs with petroleum ether, ethyl acetate, chloroform, ethanol and distilled water in soxhlet apparatus. The extracts were concentrated to dryness in rota evaporator till free from the solvents.

Isolation of fractions

Thin-layer chromatography method was carried out using silica gel aluminum plate 60F-254, 0.5 mm (TLC plates,

Merck). The spots were visualized in UV light and 10% of H₂SO₄ in methanol. The ethanolic extract was subjected to column chromatography (silica gel 60-100) for further purification. The equilibration of column was carried for one hour with petroleum ether at flow rate 5ml/min. The sample was (2 gm dissolve in acetone) loaded on to the column, 8 fractions were collected using petroleum ether:ethyl acetate (4:1), petroleum ether:ethyl acetate (1:1), petroleum ether:ethyl acetate (2:3), ethyl acetate (100%), chloroform:methanol (9:1), chloroform:methanol (1:1) and chloroform:methanol (2:8).

Above yielded product were pooled into five fractions based on TLC. The yield and appearance of the five fractions was fraction A 50 mg/gm & yellow, fraction B 300 mg/gm & black, fraction C 150 mg/gm & green, fraction D 200 mg/gm & darkish brown and fraction E 150 mg/gm & saffron.

Phytochemical analysis

Phytochemical analysis¹⁹ of fractions was carried out for the presence of alkaloids, tannins, saponins, glycosides, terpenoids, carbohydrates, flavonoids, proteins, amino acids, fixed oils, steroids & sterols by different methods.

Experimental design

Albino rats of wistar strain weighing 150-200 gm were purchased from National Institute of Nutrition, Hyderabad. The rats were kept in polypropylene cages (3 in each cage) at an ambient temperature of 25 ± 2°C and relative humidity of 55–65%. A 12 hrs light and dark schedule was maintained in the air conditioned animal house. All the rats were fed with common diets for week after arrival and then divided into groups with free access to food and water.

Acute toxicity studies

Toxicological studies were conducted in 3 groups of 5 mice and the extract is administered at the doses of 150, 300 and 1000 mg/kg no mortality was observed. They were observed continuously for 1 hr for any gross behavioral changes, symptoms of toxicity and mortality if any after dosing with *Michelia nilagirica* ethanol extract.

Study design

Rats were divided into 6 groups of six animals in each.²⁰

Group I : Received Tween 80

Group II : Paracetamol (2 gm/kg)

- Group III : Silymarin (100 mg/kg)
 Group IV : Fraction A (70 mg/kg)
 Group V : Fraction B (70 mg/kg)
 Group VI : Fraction C (70 mg/kg)
 Group VII : Fraction D (70 mg/kg)
 Group VIII : Fraction E (70 mg/kg)

Given orally the following treatment for seven days. On the seventh day, paracetamol suspension was administered at a dose of 2 gm/kg body wt., p.o., to rats of groups III, IV, V, VI, VII and VIII.

Biochemical estimation

After 24 hrs of the last treatment, blood was collected from retro-orbital plexus, serum was separated by centrifugation at 10000 rpm for 15 min. The serum was then collected and analyzed for various biochemical parameters like Aspartate transaminase (AST), Alanine transaminase²¹ (ALT), Alkaline phosphatase²² (ALP) and bilirubin²³

Histopathological studies

The liver tissue was collected, fixed in 10% formalin and stained with hematoxylin and eosin for photomicroscopic observation.²⁴

Statistical analysis

The data was represented as Mean \pm SD. Results were analysed by One-Way ANOVA followed by Dunnett's multiple comparison test using SPSS software. The minimum level of significance was set at p<0.05.

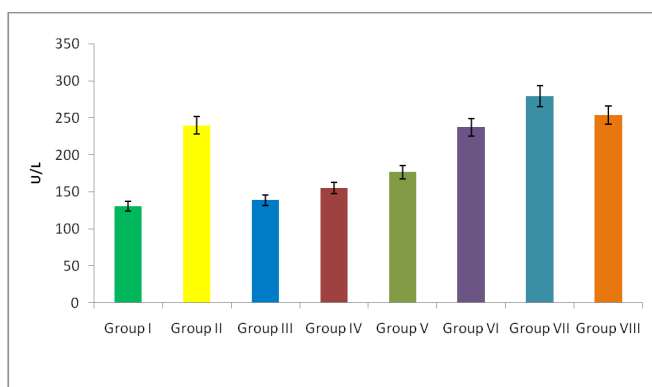


Figure 1: Effect of *Michelia nilagirica* on rat serum (AST) after paracetamol administration

RESULTS

Preliminary phytochemical screening

Phytochemical screening revealed the presence of flavonoids & amino acids in fraction A, terpenoids & proteins in fraction B, terpenoids in fraction D and alkaloids, tannins, carbohydrates & flavonoids in fraction E.

Biochemical parameters

Acute paracetamol administration significantly increased the level of liver injury marker enzymes like AST, ALT, ALP and bilirubin (The liver marker enzymes were 240 \pm 2.8 U/L, 185.5 \pm 9.8 U/L, 647.8 \pm 39.5 U/L and 2.18 \pm 0.31 mg/dl for the SGOT, SGPT, ALP and bilirubin respectively). Pretreatment with fraction A (70 mg/kg) and fraction B (70 mg/kg for seven days) reduced raising serum enzymes in hepatotoxic rats (The liver marker enzymes were 155.5 \pm 15.5, 121 \pm 3.53, 427.5 \pm 14.8 & 1.15 \pm 0.23 for fraction A and 176.8 \pm 13.4, 122.3 \pm 10.6, 497 \pm 7.07 & 1.56 \pm 0.45 for fraction B for the biochemical parameters the AST, ALT, ALP & bilirubin respectively). Pretreatment with fraction C, D and E (70 mg/kg) resulted no significant changes in Serum AST, ALT, ALP & bilirubin levels compare to paracetamol induced hepatotoxic rats (Figures 1-5).

Histopathological examination

Photographs showing histopathology of liver sections (5-10 μ), 40X, Haematoxylin-eosin stain. A) Control group (tween 80) showed normal histology, B) Paracetamol (2 gm/kg) treated group showed cellular degeneration, hydropic changes, fatty changes with wide spread hepatocellular necrosis, C) Silymarin (100 mg/kg) + paracetamol (2 mg/kg) treated group showed very little necrosis or degeneration, D) Fraction A (70 mg/kg) + paracetamol

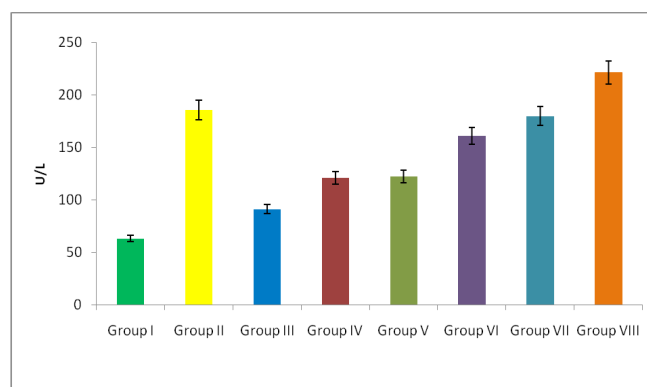


Figure 2: Effect of *Michelia nilagirica* on rat serum (ALP) after paracetamol administration

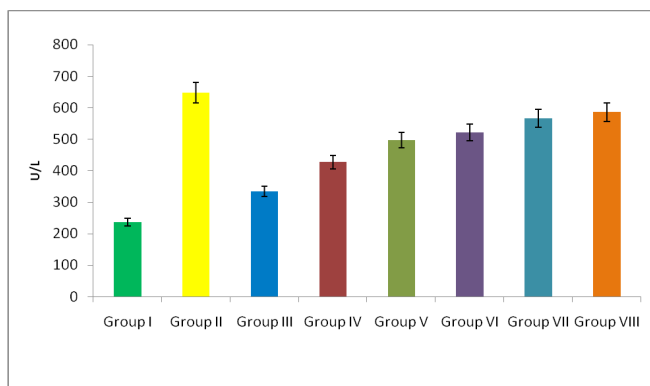


Figure 3: Effect of *Michelia nilagirica* on rat serum (ALT) after paracetamol administration

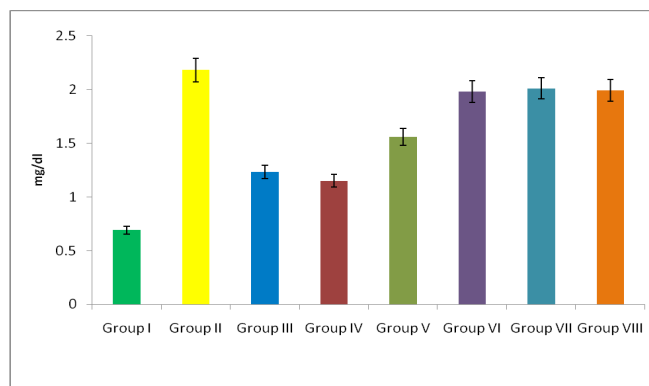


Figure 4: Effect of *Michelia nilagirica* on rat Serum bilirubin after paracetamol administration

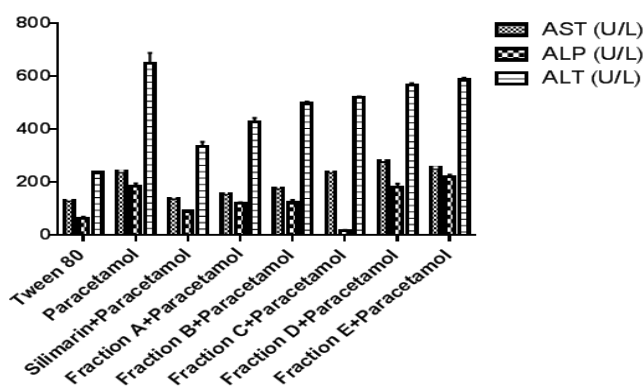


Figure 5: Comparison of AST, ALP & ALT values of different fractions

(2 mg/kg) treated group showed no hepatocellular damage except areas of focal degeneration and sinusoidal dilation, E) Fraction B (70 mg/kg) + paracetamol (2 mg/kg) treated group showed minimal hepatocellular damage, fatty changes and loss of liver architecture, F) Fraction C extract (70 mg/kg) + paracetamol (2 mg/kg) treated group showed hepatic necrosis, cellular degeneration, hydropic changes and fatty changes, G) Fraction D extract (70 mg/kg) + paracetamol (2 mg/kg) treated group showed hepatocellular damage and fatty changes, H) Fraction E extract (70 mg/kg) + paracetamol (2 mg/kg) treated group showed hepatic necrosis, cellular degeneration, hydropic changes and fatty changes (Figure 6).

DISCUSSION

Paracetamol is a common analgesic and antipyretic drug. Several studies have demonstrated the induction of hepatocellular damage or necrosis by paracetamol higher doses in experimental animals and humans.²⁵ For screening of hepatoprotective agents, paracetamol-induced

hepatotoxicity has been used as a reliable method. Paracetamol is metabolized primarily in the liver and eliminated by conjugation with sulfate and glucuronide, and then excreted by the kidney. Moreover, paracetamol hepatotoxicity has been attributed to the formation of toxic metabolites, when a part of paracetamol is activated by hepatic cytochrome P-450 to a highly reactive metabolite N-acetyl-p-benzoquinoneimine²⁶ (NAPQI). Toxic metabolites (N-acetyl-p-benzoquinoneimine) can alkylate and oxidise intracellular GSH, which results in liver GSH depletion subsequently leads to increased lipid peroxidation by abstracting hydrogen from a polyunsaturated fatty acid and ultimately, liver damage due to higher doses of paracetamol.^{27,28} Reactive metabolites can exert initial cell stress through a wide range of mechanisms including depletion of glutathione (GSH) or binding to enzymes, lipids, nucleic acids and other cell structures.²⁹

Acute paracetamol administration significantly increased the level of liver injury marker enzymes like AST, ALP, ALP and bilirubin (The liver marker enzymes were 240 ± 2.8 U/L, 185.5 ± 9.8 U/L, 647.8 ± 39.5 U/L and

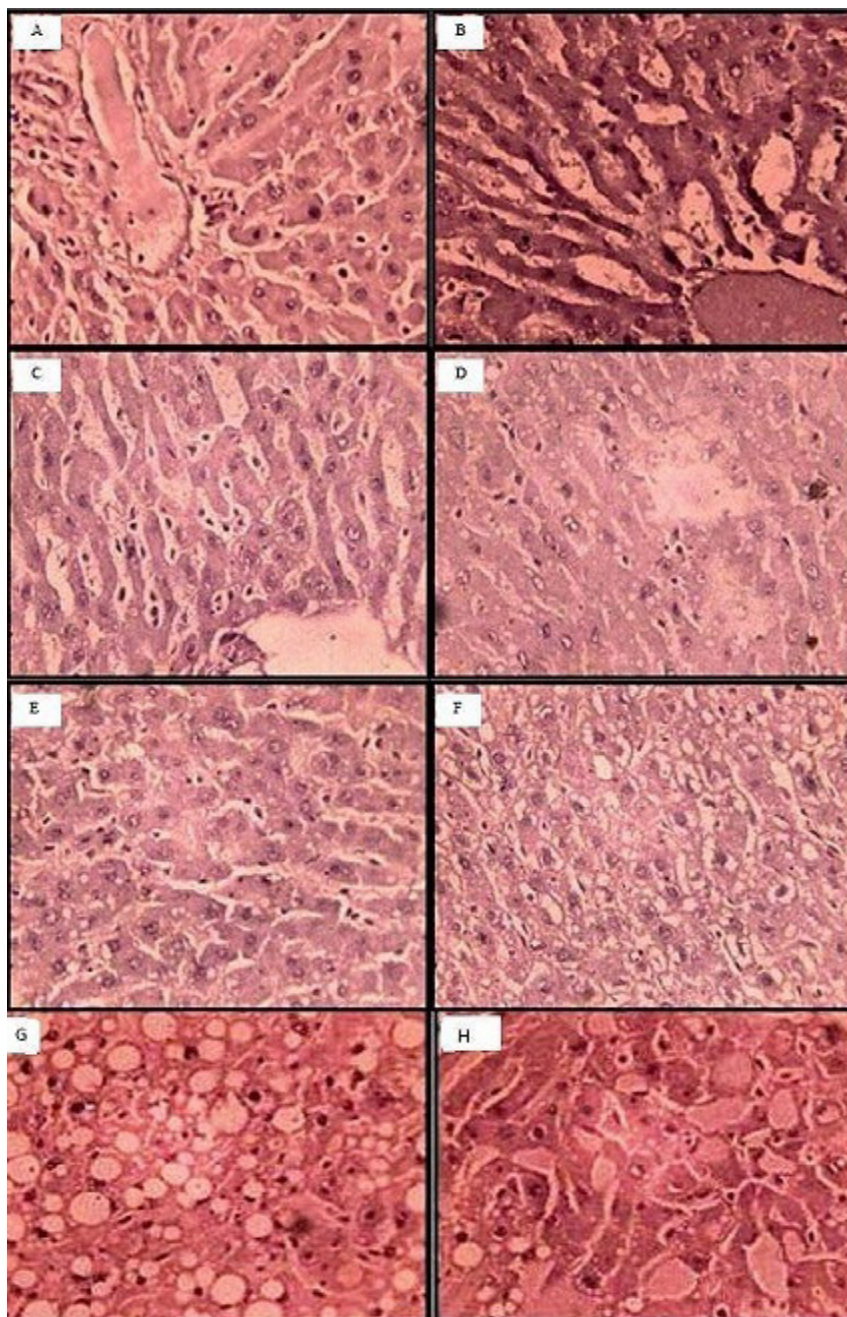


Figure 6: Histopathological section of liver tissue of albino rats

A) Control group (tween 80) showed normal histology, B) Paracetamol (2 gm/kg) treated group showed cellular degeneration, hydropic changes, fatty changes with wide spread hepatocellular necrosis, C) Silymarin (100 mg/kg) + paracetamol (2 mg/kg) treated group showed very little necrosis or degeneration, D) Fraction A (70 mg/kg) + paracetamol (2 mg/kg) treated group showed no hepatocellular damage except areas of focal degeneration and sinusoidal dilation, E) Fraction B (70 mg/kg) + paracetamol (2 mg/kg) treated group showed minimal hepatocellular damage, fatty changes and loss of liver architecture, F) Fraction C extract (70 mg/kg) + paracetamol (2 mg/kg) treated group showed hepatic necrosis, cellular degeneration, hydropic changes and fatty changes, G) Fraction D extract (70 mg/kg) + paracetamol (2 mg/kg) treated group showed hepatocellular damage and fatty changes, H) Fraction E extract (70 mg/kg) + paracetamol (2 mg/kg) treated group showed hepatic necrosis, cellular degeneration, hydropic changes and fatty changes.

2.18 ± 0.31 mg/dl for the AST, ALP, ALP and bilirubin respectively). A similar experimental procedure also used by other researchers to report the hepatoprotective effect of natural products.³⁰

The present study reported the degree of protection, measured by using biochemical parameters like AST, ALT,

ALP and bilirubin in fractions treated rats.

Studies showed that the pretreatment with *Michelia nilagirica* fraction A (70 mg/kg) for seven days offers considerable protection (P<0.05) to liver as evidenced from the levels of biochemical parameters (The liver marker enzymes were 155.5 ± 15.5, 121 ± 3.53, 427.5 ± 14.8 & 1.15 ± 0.23 for

Table 1: Phytochemical screening of the various fractions

Phytochemicals	Fraction A	Fraction B	Fraction C	Fraction D	Fraction E
Alkaloids	----	----	----	----	+
Tanins	----	----	----	----	+
Saponins	----	----	----	----	----
Glycosides	----	----	----	----	----
Terpinoids	----	+	----	+	----
Carbohydrates	----	----	----	----	+
Flavonoids	+	----	----	----	+
Proteins	----	+	----	----	----
Aminoacids	+	----	----	----	----
Fixed oils	----	----	----	----	----
Steroids & Sterols	----	----	----	----	----

Table 2: Effect of *Michelia nilagirica* on the serum AST, ALP, ALT & bilirubin levels on albino rats

Group	Treatment	AST (U/L)		ALP (U/L)		ALT (U/L)		Bilirubin (mg/dl)	
		Mean	SD	Mean	SD	Mean	SD	Mean	SD
I	Tween 80	131.1	5.6	63.2	6.4	236	4.24	0.69	0.03
II	Paracetamol (2 gm/kg)	240	2.82	185.5	9.89	647.8	39.59	2.18	0.31
III	Sylimarine (100 mg/kg) + Paracetamol (2 gm/kg)	138.8	7.77	91.3	1.41	333.5	19.09	1.23	0.2
IV	Fraction A (70 mg/kg) + Paracetamol (2 gm/kg)	155.5	15.5	121	3.53	427.5	14.8	1.15	0.23
V	Fraction B (70 mg/kg) + Paracetamol (2 gm/kg)	176.8	13.4	122.3	10.6	497.3	7.07	1.56	0.45
VI	Fraction C (70 mg/kg) + Paracetamol (2 gm/kg)	237.6	16.9	160.8	2.9	521	2.8	1.98	0.33
VII	Fraction D (70 mg/kg) + Paracetamol (2 gm/kg)	279.5	28.2	180	14.8	566.5	7.01	2.01	0.58
VIII	Fraction E (70 mg/kg) + Paracetamol (2 gm/kg)	254	2.51	221.5	7.05	586.1	8.48	1.99	0.46

the AST, ALT, ALP and bilirubin respectively) and similarly fraction B (70 mg/kg) significantly ($P < 0.05$) reduced raising serum enzymes in hepatotoxic rats (Table 1). Pretreatment with fraction D and E (70 mg/kg) resulted no significant reduction in serum AST, ALT, ALP and bilirubin compared to fraction A and B treated groups (Table 2).

CONCLUSION

Flavonoids³¹ are a class of secondary plant phenolics found in fruits, vegetables and foods, which act as pharmacological active compound in many medicinal plants. Many of the biological action of flavonoids³² have been attributed their powerful antioxidant properties³³ and number of scientific reports indicated that certain flavonoids, terpenoids have

protective effect on liver due to its antioxidant properties.³⁴

Present study fraction A contain valuable flavonoids, that shown hepatoprotective activity through regulatory action on cellular permeability, stability and suppressing oxidative stress by their antioxidant property.

CONFLICT OF INTEREST

Authors declared no conflict of interest.

ACKNOWLEDGEMENT

Authors are sincerely thankful to Prof K Madava Chetty, Plant Taxonomist, Department of Botany, Sri Venkateswara

University, Tirupati, India for authentication of plant materials. Authors are thankful to V. V. Institute of

Pharmaceutical Sciences, Gudlavalleru, India for providing necessary facilities of research work.

Highlights of Paper

- *Michelia nilagirica* belonging to the family Mangoliaceae is commonly used by many traditional healers in most of the herbal preparations for diabetes and kidney diseases.
- Different fractions isolated from ethanolic extract of whole plant of *Michelia nilagirica* is investigated for hepatoprotective activity in wistar albino rats against paracetamol induced hepatic injury.
- Rats were divided into eight groups. Each group contains six animals. Hepatic injury was achieved by injecting paracetamol at a dose of 2 mg/kg p.o.
- The hepatoprotective action is seen with fraction A by reduction in serum marker enzymes like aspartate transaminase (AST), alanine transaminase (ALT). It also reduced the elevated levels of alkaline phosphatase (ALP) & serum bilirubin.
- Histopathological studies further confined the hepatoprotective activity of fraction A against paracetamol treated group. The results obtained were compared with silymarin (100 mg/kg, orally), a standard drug.

Author Profile



- **Shaik Aminabee:** Presently working as Assistant Professor in the Department of Pharmacology in V. V. Institute of Pharmaceutical Sciences, Gudlavalleru. She has 10 papers in various National and International Journals. She participated in 05 Seminars, Conferences and Workshops. She presented 11 scientific papers in various Seminars and Conferences and received 03 prizes.



- **Dr. Atmakuri Lakshmana Rao:** He is having 15 years of Teaching and Research experience and serving as Professor and Principal of V. V. Institute of Pharmaceutical Sciences, Gudlavalleru. He guided 03 Ph.D. candidates and 18 M.Pharm. Candidates. He conferred with Meritorious University Best Teacher Award from Jawaharlal Nehru Technological University Kakinada, Kakinada. He is ratified as Principal by Jawaharlal Nehru Technological University Kakinada, Kakinada and ratified as Associate Professor by Andhra University, Visakhapatnam. He received Dr. P.D. Sethi Annual Award Certificate of Merit from Anchrom Enterprises (I) Pvt. Ltd., Mumbai. He is Faculty Accreditation and Evaluation Member, International Accreditation Organization, USA. He is given 5 Guest Lectures in different universities. He published 158 papers in various International and National Journals. He published 2 e-Books. He is Editor-in-Chief, Reviewer and Editorial Board Member for 40 reputed International and National journals. He organized 11 Seminars, Conferences and Workshops. He participated in 62 Seminars, Conferences and Workshops. He presented 27 scientific papers in various Seminars and Conferences and received 09 prizes. He is having memberships in 10 Professional Societies.



- **Dr. Maram Chinna Eswaraiah:** He is having 10 years of Teaching experience and serving as Professor and Principal of Anurag Pharmacy College, Kodad. He guided 18 M.Pharm. Candidates. He is ratified as Associate Professor by Jawaharlal Nehru Technological University Hyderabad, Hyderabad. He received UGC Fellowship Award. He published 45 papers in various International and National Journals. He participated in 12 Seminars, Conferences and Workshops. He is given 1 Guest Lecture. He is awarded Best Research Paper from Andhra University, Visakhapatnam.

REFERENCES

1. Maton A, Jean H, Charles William M, Susan J, Maryanna Quon W, David L. Human Biology and Health. Englewood Cliffs, New Jersey, USA: Prentice Hall; 1993.
2. Thewfweld W. The enzymatic methods for determination of serum AST and ALT. Dtsch. Med. 1974; 99(2): 343.
3. Kind PR, King EG. Enzymatic determination of serum alkaline phosphatase (ALP). J. Clin. Path. 1954; 7(4): 322.
4. Quereshi AA, Prakash T, Patil T. Hepatoprotective activity of *Calotropis procera* flowers against paracetamol induced hepatic injury in rats. Fitoterapia 2007; 78(7): 451-4.
5. Ranawat L, Patel J. Hepatoprotective activity of ethanolic extracts of bark of *Zanthoxylum armatum* DC in CCl₄ induced hepatic damage in rats. J. Ethnopharmacol. 2009; 124(2): 171-5.
6. Srinivasan K. Plant foods in the management of diabetes mellitus. Spices as beneficial antidiabetic food adjuncts. Int. J. Food Sci. Nutr. 2005; 56(6): 399-414.
7. Soltan ME, Sirry SM. Usefulness of some plant flowers as natural acid-base indicators. J. Chin. Chem. Soc. 2002; 49(1): 63-8.
8. Khan MR, Kihara M, Omoloso AD. Antimicrobial activity of *Michelia champaca*. Fitoterapia 2002; 73(7): 744-8.
9. Sobhagini N, Soumit KB, Malaya KM. Ethno-medico-botanical survey of Kalahandi district of Orissa. Indian J. Trad. Knowledge. 2004; 3(1): 72-9.
10. Vimala R, Nagarajan S, Alam M, Susan T, Joy S. Anti-inflammatory and antipyretic activity of *Michelia champaca* Linn., (white variety), *Ixora brachiata* Roxb. and *Rhynchosia cana* (Willd.) D.C. flower extract. Indian J. Exp. Biol. 1997; 35(12): 1310-4.
11. Ulla J, Vijaya K, Shantini S. Sesquiterpene lactones from *Michelia champaca*. Phytochem. 1995; 39(4): 839-43.
12. Takahashi M, Fuchino H, Satake M, Agatsuma Y, Sekita S. *In vitro* screening of leishmanicidal activity in myanmar timber extracts. Biol. Pharm. Bull. 2004; 27(6): 921-5.

13. Nagarajan NS, Muruges N, Thirupathy KP, Radha N, Murali A. Antidiabetic and antihyperlipidemic effects of *Cleome feline*. *Fitoterapia* 2005; 76(1): 310-5.
14. Nalamolu KR, Srinivasu N. Antidiabetic and Renoprotective effects of chloroform extract of *Terminalia chebula* seeds in streptozotocin induced diabetic rats. *BMC Complement Altern. Med.* 2006; 6(1): 17. doi: 10.1186/1472-6882-6-17.
15. Phuong ML, Ali BA, Aziz E, Abdellatif S, Yahia C, Pierre SH. The petroleum ether extract of *Nigella sativa* exerts lipid lowering and insulin-sensitizing action in the rats. *J. Ethnopharmacol.* 2004; 94(3): 251-9.
16. Grosser T, Smyth E, Fitzgerald GA. Anti-inflammatory, antipyretic and analgesic agents, pharmacotherapy of gout. *Goodman and Gillmans The Pharmacological basis of therapeutics* 2006; 4(4): 983.
17. Tripathi KD. *Essentials of Medical Pharmacology*. Medical Publishers Pvt. Ltd; 2008. 198-9.
18. Chattopadhyay RR. *Advances in Phytomedicine: etnomedicine and drug discovery*. *J. Ethnopharmacol.* 2003; 89(6): 217-9.
19. Khandelwal KR. *Practical Pharmacognosy Techniques and Experiments*. Nirali Prakashan, New Delhi. 2000; 149-56.
20. Seth UK, Dadkar NK, Kamat UG. *Selected Topics in Experimental Pharmacology*. Kothari Book Depot; 1972. 26.
21. Reitman S, Frankel S. *In vitro* determination of transaminase activity in serum. *Am. J. Clin. Pathol.* 1957; 28(4): 56-63.
22. Kind PR, King E.J. Estimation of plasma phosphatase by determination of hydrolysed phenol with amino antipyrine. *J. Clin. Pathol.* 1954; 7(4): 322-30.
23. Malloy HJ, Evelyn KA. The determination of bilirubin with the photoelectric colorimeter. *J. Biol. Chem.* 1937; 119(2): 481-90.
24. Luna LG. *Manual in histology and staining methods* (3rd ed.) McGraw-Hill. New York; 1999.
25. Vermeulen NPE, Bessems JGM, Vandestreat R. Paracetamol (acetaminophen)-induced toxicity: Molecular and biochemical mechanisms, analogues and protective approaches. *Drug Metab. Rev.* 1992; 24(1): 367-407.
26. Savides MC, Oehme FW. Acetaminophen and its toxicity. *J. Appl. Toxicol.* 1983; 3(2): 95-111.
27. Mitchell JR, Jollow DJ, Potter WZ, Gillette JR, Brodie BB. Acetaminophen-induced hepatic necrosis. *J. Pharmacol. Exp. Ther.* 1973; 187(3): 211-7.
28. Grypioti AD. Liver oxidant stress induced by paracetamol overdose. *The Internet J. Pharmacol.* 2006; 4(2): 7.
29. Pauli-Magnus C, Stieger B, Meier Y, Kullak-Ublick GA, Meier PJ. Sequence analysis of bile salt export pump (ABCB11) and multidrug resistance p-glycoprotein 3 (ABCB4, MDR3) in patients with intrahepatic cholestasis of pregnancy. *Hepatology*. 2005; 43(2): 342-57.
30. Kumar G, Banu GS, Pappa PV, Sundararajan M, Pandian MR. Hepatoprotective activity of *Trianthema portulacastrum* L. against paracetamol and thioacetamide intoxication in albino rats. *J. Ethnopharmacol.* 2004; 92(1): 37-40.
31. Nawwar MAM, Ishak MS, Michael HN, Buddrust J. Leaf flavonoid of *Ziziphus spina-christi*. *Phytochem.* 1984; 23(9): 2110-1.
32. Harborne JB. *The Flavonoids: Advances in research since 1980*. Chapman & Hall, London; 1988.
33. Ardestani A, Yazdanparast R. Antioxidant and free radical scavenging activity of *Achillea santolina* extracts. *Food chem.* 2007; 104(1): 21-9.
34. Alqasoumi SI, Abdel-Kader MS. Terpenoids from *Juniperus procera* with hepatoprotective activity. *Pak. J. Pharm. Sci.* 2012; 25(2): 315-22.